Prostate biopsies using both gray scale and 3D color flow power Doppler ultrasound (3DCFPDU)

ASCO 2015 Genitourinary Cancer Symposium

February 26-28, 2015

Authors

Michael J. Dattoli, MD – Physician-in-Chief

Richard A. Sorace, MD, PhD – Medical Director
- Dattoli Cancer Center & Brachytherapy Research Institute Sarasota, Florida

Stephen M. Bravo, MD
- University of Central Florida Assistant Professor Orlando, Florida
- Sand Lake Imaging – Founder Orlando, Florida

David Bostwick, MD – Founder
- Bostwick Laboratories Richmond, Virginia; Orlando, Florida

About the Presenter

Dattoli attended the University of California at Berkeley and was the valedictorian of his class at Vassar College; he earned his medical degree at **Mount Sinai School of Medicine,** Radiation Oncology at **New York University Medical Center,** then distinguished himself at **Memorial Sloan-Kettering Cancer Center** and **New York Hospital-Cornell University Medical Center,** as the **Special Fellow in Brachytherapy.** He was appointed Assistant/Associate Professor in Brachytherapy and Radiation Oncology at Memorial Sloan- Kettering Cancer Center in New York and at New York Hospital-Cornell University Medical Center prior to relocating to Florida. A pioneer in the application of brachytherapy for prostate cancer, Dr. Dattoli is the co-author of three editions of the textbook **Prostate Brachytherapy Made Complicated,** as well principal author of **Surviving Prostate Cancer Without Surgery, The Dattoli Blue Ribbon Prostate Cancer Solution,** a dozen booklets on prostate cancer subjects, and more than 100 journal articles and abstracts. He has published the longest prostate cancer cure rate study on intermediate and high risk prostate cacner in the medical literature In 2000, with partner Richard Sorace, MD, PhD, he founded the **Dattoli Cancer Center & Brachytherapy Research Institute** in Sarasota, FL. **www.dattoli.com**

Background

Prostate Cancer (CAP) diagnosis has historically been identified through random biopsies using transrectal ultrasound guided biopsies (TRUS).

Today's standard protocol typically consists of an "extended pattern" 10-12 core biopsy method.

This often leads to sampling errors with mixed diagnosis, delayed diagnosis and the need for repeated biopsies, under staging and finding indolent malignancies leading to over treatment. Infection is not uncommon when using standard TRUS, which is avoided when using sterile transperineal methods.

Advantages in 3D color flow power Doppler ultrasound (3DCFPDU) suggest that more selective biopsies are superior to standard TRUS biopsies, resulting in a higher yield of CAP.

Methods

192 consecutive patients were biopsied using 3DCFPD between February 2012 and July 2014. Patients were positioned in the extended dorsolithotomy position allowing maximal visualization of all regions of the prostate regardless of size. Local anesthesia was utilized. The median number of biopsies per patient was eight (8). Only 3 patients had not undergone previous biopsies and median previous biopsies = 2.

We studied tumor detection rate using combined gray scale and 3DCFPDU with directly sampling of specific regions using the transperineal brachytherapy template guided method as a simple outpatient procedure.

Continued...

Methods continued

Inclusion criteria consisted of abnormal DRE, PSA kinetics 0.75ng/mg/yr, PSA >10 and % free PSA <17, PSA density 0.27. Cores were stratified into 4 risk groups:

1. Hypoechoic only lesion (72 patients, 648 cores)
2. Hypervascular only lesion (26 patients, 182 cores)
3. Hypoechoic lesion associated with hypervascular pulsatile vessels which were synchronous and coinciding with normal cardiac pulse using duplex analysis (32 patients, 256 cores)
4. Hypoechoic lesion associated with non-pulsatile vessels suggesting independent vascular flow consistent with neoplasm also using duplex analysis (62 patients, 434 cores)

NOTE: Isoechoic regions were not biopsied. Subgroups were analyzed using chi-square, student t-test and logistic regression.

Results

The diagnosis yield associated with Group 4 was statistically significantly higher compared to:

Risk Group 1. 20% biopsy positive ($p < 0.5$)
Risk Group 2. 19% biopsy positive ($p < 0.3$)
Risk Group 3. 55% biopsy positive ($p < 0.1$)
Risk Group 4. 97% biopsy positive ($p < 0.01$)

Only group 4 revealed a greater Gleason 7-10 CAP ($p < 0.03$).

Conclusions

Transperineal template guided biopsies using gray scale and 3DCFPDU are both highly effective and cost effective.

This may lead to reducing the number of prostate biopsies performed resulting in reduced post-procedure morbidity, more accurate staging while allowing for enhanced detection of serious CAP by targeting the most suspicious lesions.

Additional research should study the diagnostic gain associated with 3DCFPDU.

Group 1
Hypoechogenic only lesion
(72 patients, 648 cores)

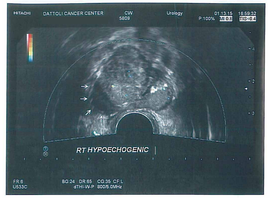

Group 2
Hypervascular only lesion
(26 patients, 182 cores)

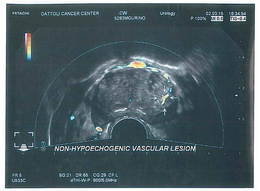

Group 3
Hypoechogenic lesion associated with pulsatile vessels
(32 patients, 256 cores)

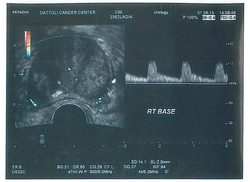

Group 4
Hypoechogenic lesion associated with non-pulsatile vessels
(62 patients, 434 cores)

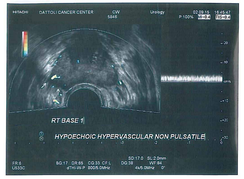

Group 4
(Continued)

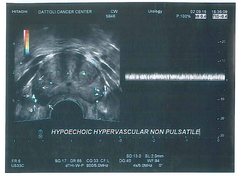

Inclusion criteria consisted of abnormal DRE, PSA kinetics 0.75ng/mg/yr, PSA >10 and % free PSA <17, PSA density 0.27. Cores were stratified into 4 risk groups:

1. Hypoechoic only lesion (72 patients, 648 cores)
2. Hypervascular only lesion (26 patients, 182 cores)
3. Hypoechoic lesion associated with hypervascular pulsatile vessels which were synchronous and coinciding with normal cardiac pulse using duplex analysis (32 patients, 256 cores)
4. Hypoechoic lesion associated with non-pulsatile vessels suggesting independent vascular flow consistent with neoplasm also using duplex analysis (62 patients, 434 cores)

NOTE: Isoechoic regions were not biopsied.
Subgroups were analyzed using chi-square, student t-test and logistic regression.